



PATIENT

Rhino Sipes

SPECIES

Canine

BREED

Pitbull

SEX

Male Neutered

AGE

9.18.10

WEIGHT

65lbs

INTERPRETED BY

Maggie Machen Lamy,
DVM, DACVIM
(Cardiology)

HOSPITAL NAME

Mt Airy Animal
Hospital

REFERRING VET

Dr. Riley

INVOICE

30210

DATE

4.12.23

PRESENTING CLINICAL SIGNS

History: New murmur/cough.

-Pertinent abnormal PE/Chem/CBC/UA Results: Enlarged heart on rads.

-Current medications: None listed.

-Sedation used: Not required to complete full diagnostic ultrasound.

-Pertinent previous ultrasound results: No previous.

-STAT: Not requested

-Imaging performed by: Stephanie Warga RDCS, RVT.

ECHOCARDIOGRAM FINDINGS

2D, m-mode, color flow and doppler imaging is available. Mild diffuse thickening of mitral valve leaflets with no prolapse into the left atrial lumen. Mild to moderate eccentric mitral regurgitation with no left atrial dilation. Normal MR velocity. Normal LV diameter with mildly depressed myocardial function. The tricuspid valve appears normal with trace tricuspid regurgitation. Normal velocity. Normal right atrial and ventricular diameter and morphology indicating no overt evidence of pulmonary arterial hypertension. The pulmonic and aortic valves are normal in morphology and mobility. Normal pulmonic and aortic outflow velocities with laminar flow. No obvious aortic or pulmonic insufficiency. No pericardial or pleural effusion noted. No obvious cardiac masses.

CARDIAC CHART

CANINE CARDIAC PARAMETERS	MR VMAX (m/s)	TR VMAX (m/s)	LA/AO (Boon method)	LA/AO (Heart Base; Swe)	FS (%)	EF (%)	EPSS (cm)
NORMAL PARAMETER	4.5-5.5	<2.7	1.3	<1.6	28-40	40-100	<0.6
PATIENT	5.0	2.2	NM	1.2	24	42	NM
CANINE CARDIAC PARAMETERS	HR (BPM)	AV VMAX (m/s)	PV MAX (m/s)	BODY WEIGHT (kg)	LA 2D short axis Base view (cm)	LVIDd Avg; 2D and m-mode short axis (cm)	LVIDs Avg; 2D and m-mode short axis (cm)
NORMAL PARAMETER	50-100	0.7-1.7	0.7-1.6	BELOW	BELOW	BELOW	BELOW
PATIENT	100	1.2	0.6	29.5	3.0	4.5	3.4
*Normal chamber parameters expressed as a mean value (SD)				3	1.27 (5.3)	2.46 (2.46)	1.36 (5.5)
BODY WEIGHT DEPENDENT PARAMETERS				5	1.40 (4.5)	2.74 (5.2)	1.60 (4.7)
<i>*Note: All measurements based upon multi-modal images and methods. An average value is reported.</i>				10	1.50 (3.8)	3.27 (3.5)	2.06 (3.1)
				15	1.83 (2.0)	3.71 (2.4)	2.43 (2.1)
				20	2.02 (1.9)	4.14 (2.2)	2.80 (2.0)
				25	2.18 (2.4)	4.48 (2.9)	3.10 (2.5)
				30	2.33 (3.3)	4.83 (3.9)	3.39 (3.4)
				35	2.48 (4.3)	5.17 (5.0)	3.69 (4.5)
				40	2.62 (5.2)	5.48 (6.1)	3.96 (5.4)
				50	2.88 (7.1)	6.07 (8.3)	4.46 (7.4)

Adapted from June Boon, Veterinary Echocardiography, 1998
Rishniw M and Hollis NE, J Vet Intern Med 2000; 14:429-435
Hansson et al, Vet Rad and Ultrasound 2002
Bonagura et al. Echocardiography: principles of interpretation, Vet Clin North Am 15:1177, 1995

INTERPRETATION OF THE FINDINGS & FURTHER RECOMMENDATIONS

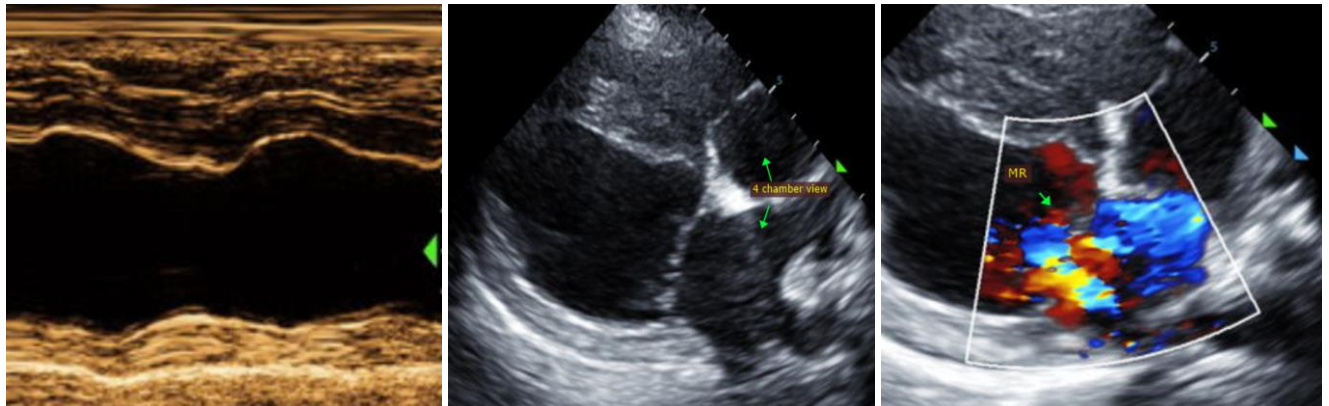
Chronic degenerative valve disease causing mild to moderate mitral and trace tricuspid regurgitation. Lack of significant left atrial enlargement indicates the current risk for complication is low. The LV function is mildly depressed, which may be a secondary phenomenon in a large breed dog. Consider screening for ancillary contributing issues, such as an atypical diet or hypothyroidism. Monitoring is recommended. No additional issues are identified.

In a dog with no significant left atrial enlargement, no cardiac medications are clearly indicated. Assessment of progression in the future will help predict long term prognosis, which is highly variable at this stage (B1). Omega fatty acid supplementation and mild salt restriction may be of some long-term benefit. Monitor for development of a cough, labored breathing, exercise intolerance or collapse episodes.

Anesthetic risk is considered mild if needed. Cardiac protective drug choices (opioid/benzodiazepine premedication, propofol or alfaxalone induction, isoflurane gas) are recommended. Pre-oxygenate for 5-10 minutes prior to induction. Monitor for arrhythmias, hypotension, and hypoxia both intra and post-operatively and intervene as necessary. Mild IV fluid restriction is recommended to avoid fluid overload. Avoid heart rate stimulating drugs such as atropine unless clinically indicated.

Recommend conservative monitoring with a recheck echocardiogram in 6 months, sooner if any development of clinical signs.

IMAGES



The information and recommendations provided are based on the images presented by the referring veterinarian. No evaluation can be communicated regarding pathology that was not visible in the image/video clips provided.

Thank you for this referral. This report was generated using transcription software, and minor dictation errors may be present. If the clinical or image interpretation does not parallel your findings or if I can be of any further assistance, please contact me.

Maggie Machen Lamy, DVM
Diplomate of the American College of Veterinary Internal Medicine (Cardiology)
info@sonopath.com